Fundamental Toxicological Sciences (Fundam. Toxicol. Sci.)
Vol.10, No.2, 59-68, 2023

The Japanese Society of Toxicology

Fundamental Toxicological Sciences

URL : http://www.fundtoxicolsci.org/index_e.html

Data Report

A 90-day dose toxicity study of 2-(2H-benzotriazol-2-yl)-6-dodecyl-4-methylphenol in rats

Makiko Kuwagata[1], Masaru Tsuboi[2], Toshime Igarashi[1], Mariko Tsurumoto[1], Takuya Nishimura[1], Yuhji Taquahashi[1] and Satoshi Kitajima[1]

[1]*Division of Cellular and Molecular Toxicology, Center for Biological Safety and Research, National Institute of Health Sciences, 3-25-26, Tonomachi, Kawasaki-ku, Kawasaki, Kanagawa 210-9501, Japan*
[2]*Research Laboratories in Vitro and in Vivo, Higashimatsuyama Laboratories, Drug Safety Testing Center Co., Ltd., 88-75, Shingo, Higashi-Matsuyama, Saitama 355-0071, Japan*

(Received January 30, 2023; Accepted February 7, 2023)

ABSTRACT — 2-(2H-benzotriazol-2-yl)-6-dodecyl-4-methylphenol (BTMLP, CAS No. 125304-04-3) is widely used as a liquid ultraviolet absorber that prevents deterioration of synthetic resins and so on. To investigate its toxicological properties and determine the no-observed-adverse-effect level (NOAEL), a 90-day repeated oral toxicological study of BTMLP was conducted in Crl:CD (SD) rats at doses of 0 (vehicle control, corn oil), 100, 300, and 1000 mg/kg/day. There was no observed mortality or abnormal clinical signs related to the treatment of any group. Body weight and food consumption were not affected by BTMLP treatment. In males, significant prolongations of prothrombin time and activated partial thrombin time were observed in the BTMLP-treated groups. Histopathological examination revealed a slight increase of the eosinophilic bodies and hyaline droplets in the renal cortical tubules in the 1000 mg/kg group in males. As mentioned above, the toxic effect of the BTMLP was noted in the blood coagulation system and kidneys only in males. Based on these findings, the NOAEL was judged to be less than 100 mg/kg/day in males and 1000 mg/kg/day in females under this study's condition.

Key words: 2-(2H-benzotriazol-2-yl)-6-dodecyl-4-methylphenol, A 90-day repeated oral toxicity study, Rats

INTRODUCTION

2-(2H-benzotriazol-2-yl)-6-dodecyl-4-methylphenol (BTMLP, Fig. 1) is one of benzotriazole ultraviolet stabilizers (BUVSs), and is widely used as a liquid ultraviolet absorber to prevent the deterioration of synthetic resins in various industrial products. BTMLP is added to plastic products, including food packaging products. According to the GHS classification (https://anzeninfo.mhlw.go.jp, https://www.nite.go.jp), the specific target organs causing toxicity after repeated exposure of BTMLP are the liver (Hazard Category 1, organ damage) and the kidney (Hazard Category 2, fear of organ damage). Some BUVSs exhibit agonistic activities toward the human aryl hydrocarbon receptors, and the endocrine-disrupting action of BUVSs. However, BTMLP was not mediated by nuclear receptors, pregnane X receptor, constitutive andros-

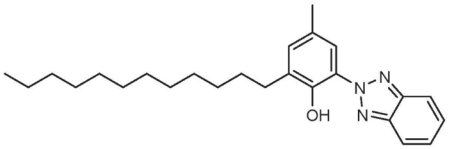

Fig. 1. Chemical Structure of 2-(2H-benzotriazol-2-yl)-6-dodecyl-4-methylphenol

Correspondence: Makiko Kuwagata (E-mail: kuwagata.m@nihs.go.jp)

tane receptor, or peroxisome proliferator-activated receptor alpha (PPAR α) in rats (Watanabe *et al*., 2019). In this study, to clarify this compound's toxicological properties and establish a no-observed-adverse-effect level (NOAEL), we examined the effects of BTMLP on toxicity for long-term exposure in rats in a 90-day repeated oral dose toxicity study.

MATERIALS AND METHODS

Test material

The test chemical, 2-(2H-benzotriazol-2-yl)-6-dodecyl-4-methylphenol (BTMLP, Fig. 1), manufactured by BLD Pharmatech Ltd. (Shanghai, China; lot no BQW562; purity 98%), was a yellowish liquid, characterized via HPLC-UV.

Biochemical research-grade corn oil was purchased from Fujifilm Wako Pure Chemical Corporation (Osaka, Japan). We used corn oil as the vehicle control because of BTMLP was easily dissolved in corn oil.

Animals and treatment

Specific pathogen-free Crl: CD (SD) rats at five weeks of age were purchased from Jackson laboratories Japan, Inc. (Kanagawa, Japan) and were housed at the Animal Facility of the Drug Safety Testing Center Co., Ltd. (DSTC) under controlled temperature and relative humidity with a 12-hr light/dark cycle (lights on at 06:00). The animals were individually accommodated in polycarbonate cages with Carefeeaz floor bedding (HAMRI Co., Ltd., Ibaraki, Japan). Pellet diet MF (Oriental Yeast Co., Ltd., Tokyo, Japan) and tap water filtrated through a 5-µm cartridge filter was given *ad libitum* to the animals.

After quarantine, rats were randomly assigned to four groups (10 rats/group/sex) based on body weight. Each group received BTMLP at 0 (vehicle control, corn oil), 100, 300, and 1000 mg/kg/day orally using a stomach gavage tube, once daily of 5 mL/kg body weight (Diehl *et al*., 2001) for 90 days (males) or 91 days (females), respectively. The doses were based on the results of the 14-day dose-finding study in which any treatment-related toxicological changes were not observed up to the 1000-mg/kg/day oral treatment.

The animal study was approved by the Animal Care and Utilization Committee of the National Institute of Health Sciences, in Japan, and the in-house animal care committee of the testing facility, DSTC. Animal husbandry, handling, and euthanasia were conducted according to the Japanese Act on Welfare and Management of Animals (2019), standards relating to the Methods of Destruction of Animals (Ministry of the Environments, 2007), measures relating to the Care and Keeping and Reducing Pain of Laboratory Animals (Ministry of the Environments, 2013), Basic Policies for the Conduct of Animal Experiments in Research Institutions Under the Jurisdiction of the Ministry of Health, Labor and Welfare (2015), and Regulations of Animal Experimental Ethics (DSTC, 2019).

A 90-day repeated oral dose toxicity study design

A 90-day repeated oral dose toxicity study of BTMLP in rats was conducted according to the Guidelines for Designation of Food Additives and for Revision of Standards for the Use of Food Additives (Ministry of Health, Laboratory, and Welfare of Japan; MHLW, 1996) in compliance with GLP standard in Standard Concerning Testing Laboratories Implementing Tests for New Chemical Substances etc. (MHLW, 2011).

The start day of treatment was designated as treatment day 1 (T1). Animal conditions were observed daily. Body weight and 24-hr food consumption were measured every week beginning the day before T1.

The urinary examination was performed on the final week of administration. Five animals/groups/sex were placed in a metabolic cage, TG-781 (Tokyo Giken Service Co., Ltd., Tokyo, Japan) with food and water. Using a fresh urine sample obtained within 4 hr after excretion, qualitative parameters including urinary urobilinogen, protein, pH, occult blood, ketone body, bilirubin, urinary sugar, and specific gravity, were measured using a Multistics SG (Siemens Healthcare Diagnostics K.K., Tokyo, Japan). The urinary volume, color, cloud (turbidity), odor and urinary sodium, potassium, and chloride levels of the 24-hr collected urine were assessed. Urinary electrolytes were determined using an automated analyzer, AU480 (Beckman Coulter, K.K., Tokyo, Japan). Moreover, the 24-hr sample was centrifuged to obtain urinary sediment for examining erythrocyte, leukocyte, epithelial cell, crystal, casts, microorganisms, and fatty globules.

Following urinary examination, eye appearance was observed, and light reflexes were examined in response to dark adaptation. Subsequently, a mydriatic, Mydrin® P (Santen Pharmaceutical Co., Ltd., Osaka, Japan), was administered to animals' eyes; the anterior part, optic media, and ocular fundus were then examined with a slit-lamp, SL-5 (Kowa Co., Ltd., Aichi, Japan), and a fundus camera, KOWA GENESIS-D (Kowa Co., Ltd.), during the final week of administration.

At autopsy, hematology and serum biochemistry were quantified via typical clinical methods. Before the autopsy, the animals fasted overnight. After being anesthetized with isoflurane, blood samples were acquired from the

abdominal aorta.

Blood samples were collected into EDTA-containing tubes for the hematology examination. Then, the whole blood was directly assayed. Red blood cell (RBC), hemoglobin (HGB), hematocrit (HCT), mean corpuscular volume (MCV), mean corpuscular hemoglobin (MCH), mean corpuscular hemoglobin concentration (MCHC), platelet (PLT), white blood cell (WBC), reticulocyte ratio (RET%), and differential leukocytes count were assess using a multiple blood cells analyzer, XT-2000*i*V (Sysmex Corporation, Hyogo, Japan).

Plasma was obtained after centrifugation with 3.2% sodium citrate, and then assayed using an automated blood coagulation analyzer, CA-620 (Sysmex Corporation), for prothrombin time (PT) and activated partial thrombin time (APTT).

After centrifugation, the serum samples were assayed using an automatic analyzer, AU480 (Beckman Coulter, K.K.) for the following: total bilirubin (T-Bil), aspartate aminotransferase (AST), alanine aminotransferase (ALT), gamma-glutamyl transpeptidase (γ-GTP), total protein (TP), albumin (Alb), globulin (Glb), total cholesterol (T-cho), triglyceride (TG), glucose (Glu), urea nitrogen (BUN), creatinine (Crea), sodium (Na), potassium (K), chloride (Cl), calcium (Ca), and inorganic phosphorus (IP).

Pathological examinations

All organs and tissues were carefully examined macroscopically to record all gross lesions. At autopsy, the heart, thymus, lungs, thyroid glands (after fixation), spleen, liver, kidneys, pituitary gland (after fixation), adrenal glands, testes, epididymides, uterus, ovaries, and brain were weighed. Lungs were immersed in fixatives following the injection fixation. Testis and epididymis were prefixed with the FSA solution, consisting of formaldehyde, sucrose, acetic acid and methanol (Muto Pure Chemical Co., Ltd., Tokyo, Japan) along with 10% neutralized buffered formalin. The eyeball was fixed with Davidson's solution. The other organs and tissues were fixed in 10% neutralized buffered formalin. After fixation, paraffin-embedded sections were prepared and stained with hematoxylin and eosin for histopathological examination. If a test material-related histopathological changes appeared in the 1000 mg/kg group, the relevant tissues from the lower dose groups were examined. In this study, histopathological examination was performed on kidney samples from all groups in males, and in all other tissues of the control and 1000 mg/kg groups. Results for male and female tissues are shown in Tables 3 and 4, respectively.

Statistical analysis

Statistical significance of the difference between the control and treated groups was estimated at ≤ 5% levels of probability via statistical tests using SAS 9.3 (SAS Institute Japan Ltd., Tokyo, Japan) and EXSUS 8.0 (EPS Corporation, Tokyo, Japan).

Quantitative parameters, such as body weight, food consumption, urinary volume, urinary electrolytes, hematological parameters, blood chemical parameters, and organ weights, were first evaluated using Bartlett's test for equality of variances. When this test showed that the variances were homogeneous between groups ($P > 0.05$), a parametric one-way analysis of variance (ANOVA) was used to determine if any statistical differences existed among groups. When the results of one-way ANOVA were significant ($P \leq 0.05$), Dunnett's multiple comparisons were performed. When the Bartlett's test showed that variances were heterogeneous between groups ($P \leq 0.05$), the data were evaluated by Kruskal-Wallis' nonparametric ANOVA. When the results were significant ($P \leq 0.05$), Steel's nonparametric test was applied. For histopathological findings, Fisher's exact and Wilcoxon's rank sum test were used.

RESULTS

General conditions

No deaths were observed in any groups during the study period. Moreover, no effects of BTMLP were seen in clinical signs, body weight (Fig. 2), food consumption (Fig. 3), ophthalmological findings, or urinary parameters.

Hematological observations and serum biochemistry

Tables 1 and 2 show the hematological and serum biochemical data, respectively.

PT and APTT prolonged in a dose dependent manner in males. The prolongation of the coagulation system was markedly observed in males in the 1000 mg/kg group. In females, there were no effects on coagulation parameters.

A significant increased α2 protein ratio in the 300 and 1000 mg/kg groups and a decreased β protein ratio in the 1000 mg/kg group in males. Other changes, such as decreased MONO%, decreased RET%, and elevations of serum Na, K, and/or Cl, were variations within the historical control data ranges of the test facility.

Pathological examinations

At autopsy, there were no macroscopic findings related to BTMLP.

Table 3 shows the data for organ weights. The relative kidney weights were significantly increased in the 1000 mg/kg

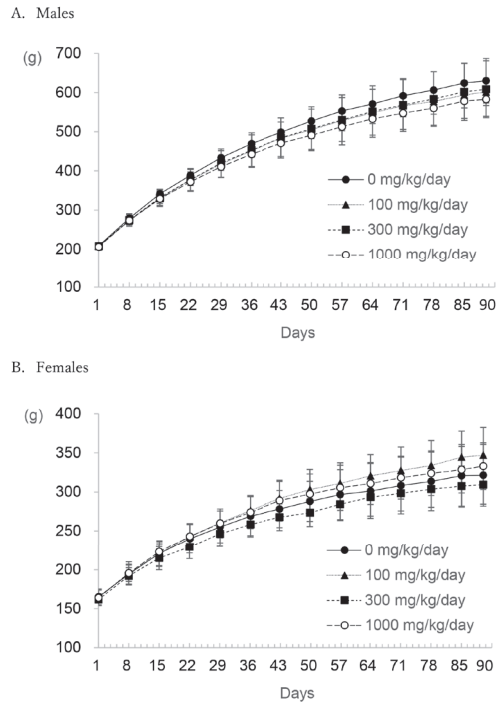

Fig. 2. Body weight of male (A) and female (B) rats treated orally with 2-(2H-benzotriazol-2-yl)-6-dodecyl-4-methylphenol for 90 days.

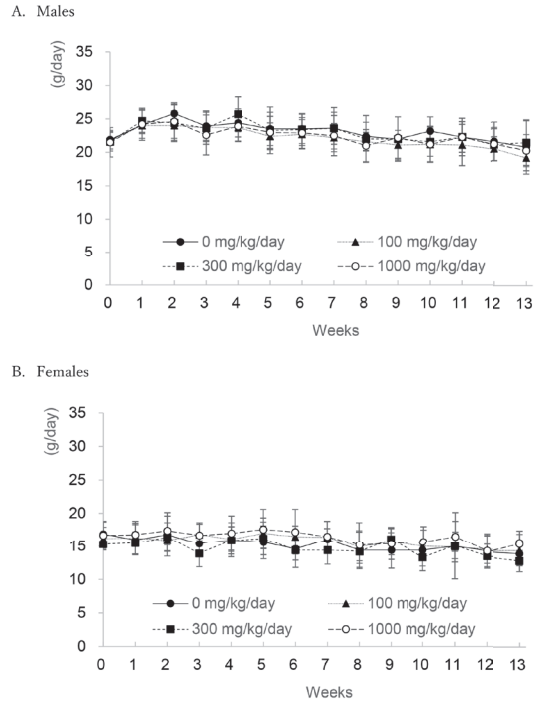

Fig. 3. Food intake of male (A) and female (B) rats treated orally with 2-(2H-benzotriazol-2-yl)-6-dodecyl-4-methylphenol for 90 days.

group in males. Thyroid weights were changed considerably in both sexes in the 100 and/or 300 mg/kg groups without any histopathological changes.

On histopathological assessment (Tables 5 and 6), treatment-related histopathological findings were noted in the kidney of males. Eosinophilic bodies and hyaline droplets in the proximal renal tubules were observed in only males, regardless of the dosage. In the 1000 mg/kg group in males, the frequency and degree of the deposits increased (Fig. 4). Several lesions in other tissues were sporadically detected, but no significant treatment-dependent alterations were apparent.

DISCUSSION

In this study, adverse effects of BTMLP were found in blood coagulation parameters and the kidney in only males.

PT and APTT in males were prolonged dose-dependently, suggesting these defects are common to intrinsic and extrinsic pathways of the blood clotting cascade. Because many coagulation factors are generated in the liver, these prolongations may have been caused by functional alteration of this organ. The changes in α2 and β protein fractions may be associated with the potential liver functional changes because many proteins in these fractions are produced in the liver. However, in this study, adverse effects relating to the liver function were limited to the prolongations of PT and APTT. In fact, neither serum TP nor Alb showed noteworthy changes, and no histopathological lesions were observed in the liver. Meanwhile, no females showed prolongations of PT and APTT. The cause of this sexual difference is unclear at present.

In the 1000 mg/kg group, increased relative kidney weights were observed in males. However, no blood biochemical changes suggestive of renal damage were observed. There was no causality between kidney weight and histopathological changes. The data of kidney weight in the 1000 mg/kg group in males, 0.6160%, are equivalent to the historical control data of the test facility (0.6166 ± 0.0898, mean ± 2SD, %). Thus, the increased relative kidney weights were considered of low toxicological significance.

Thyroid weights were significantly increased in both sexes in the 100 and/or 300 mg/kg groups, but not in the 1000 mg/kg group. Histopathologically, any changes were not observed in the thyroids. There was no evidence

Table 1. Hematology data of SD rats treated orally with 2-(2H-Benzotriazol-2-yl)-6-dodecyl-4-methylphenol for 90 days.

Dose (mg/kg/day)		0 [a)]	100	300	1000
Male (No. of animals)		10	10	10	10
RBC	($\times 10^4$/μL)	879 ± 39	872 ± 24	888 ± 43	858 ± 72
HGB	(g/dL)	15.5 ± 0.6	15.3 ± 0.6	15.8 ± 0.5	15.3 ± 0.5
HCT	(%)	43.3 ± 1.5	42.9 ± 1.5	44.1 ± 1.4	43.3 ± 1.5
MCV	(fL)	49.2 ± 1.4	49.2 ± 1.6	49.7 ± 1.8	50.8 ± 4.4
MCH	(pg)	17.7 ± 0.4	17.5 ± 0.5	17.8 ± 0.6	17.9 ± 1.2
MCHC	(g/dL)	35.9 ± 0.5	35.6 ± 0.4	35.8 ± 0.5	35.3 ± 0.6
PLT	($\times 10^4$/μL)	116.2 ± 8.9	116.1 ± 8.9	111.5 ± 6.7	104.3 ± 35.1
RET%	(%)	3.07 ± 0.77	3.01 ± 0.50	2.83 ± 0.26	2.68 ± 0.56
WBC	($\times 10^2$/μL)	110.5 ± 31.0	125.8 ± 41.1	116.9 ± 43.2	112.2 ± 20.8
NEUT	(%)	14.0 ± 2.9	11.6 ± 3.7	15.1 ± 4.0	11.6 ± 5.0
LYMPH	(%)	80.3 ± 4.1	83.3 ± 5.2	79.1 ± 5.1	84.4 ± 5.7
MONO	(%)	4.5 ± 1.5	3.9 ± 1.5	4.3 ± 1.4	2.9 ± 0.7*
EO	(%)	1.1 ± 0.4	1.2 ± 0.4	1.5 ± 0.7	1.1 ± 0.5
BASO	(%)	0.1 ± 0.1	0.0 ± 0.1	0.1 ± 0.1	0.0 ± 0.1
NEUT	($\times 10^2$/μL)	15.3 ± 4.6	14.2 ± 6.4	17.0 ± 6.2	12.7 ± 5.6
LYMPH	($\times 10^2$/μL)	89.1 ± 26.7	105.3 ± 37.3	93.7 ± 39.5	95.0 ± 20.2
MONO	($\times 10^2$/μL)	4.9 ± 1.9	4.8 ± 2.3	4.6 ± 1.0	3.2 ± 0.9
EO	($\times 10^2$/μL)	1.2 ± 0.4	1.4 ± 0.4	1.5 ± 0.3	1.2 ± 0.5
BASO	($\times 10^2$/μL)	0.1 ± 0.1	0.1 ± 0.1	0.1 ± 0.1	0.0 ± 0.1
PT	(sec.)	11.5 ± 1.5	15.1 ± 2.8**	17.3 ± 3.1**	26.1 ± 8.1**
APTT	(sec.)	18.3 ± 2.1	21.4 ± 1.6*	22.7 ± 2.3**	32.9 ± 7.5**
Female (No. of animals)		10	10	10	10
RBC	($\times 10^4$/μL)	799 ± 37	785 ± 28	791 ± 23	792 ± 28
HGB	(g/dL)	15.2 ± 0.3	14.8 ± 0.3	14.9 ± 0.4	14.7 ± 0.6
HCT	(%)	43.1 ± 1.1	42.5 ± 1.1	42.5 ± 1.3	42.5 ± 1.1
MCV	(fL)	54.0 ± 2.4	54.2 ± 1.5	53.8 ± 2.1	53.7 ± 1.8
MCH	(pg)	19.0 ± 0.9	18.9 ± 0.4	18.9 ± 0.6	18.6 ± 0.5
MCHC	(g/dL)	35.2 ± 0.6	34.9 ± 0.8	35.0 ± 0.7	34.7 ± 0.9
PLT	($\times 10^4$/μL)	103.9 ± 11.9	93.9 ± 10.7	102.1 ± 15.1	109.2 ± 14.3
RET	(%)	3.08 ± 0.47	2.94 ± 0.45	2.61 ± 0.77	2.58 ± 0.25*
WBC	($\times 10^2$/μL)	76.1 ± 26.9	70.9 ± 15.0	66.9 ± 13.7	66.5 ± 10.7
NEUT	(%)	13.6 ± 7.3	11.7 ± 4.3	14.1 ± 8.7	12.3 ± 3.3
LYMPH	(%)	81.8 ± 7.5	84.0 ± 4.4	80.9 ± 10.2	82.9 ± 3.2
MONO	(%)	2.9 ± 0.5	3.1 ± 0.9	3.5 ± 1.4	3.5 ± 0.5
EO	(%)	1.7 ± 0.9	1.2 ± 0.3	1.5 ± 0.5	1.4 ± 0.4
BASO	(%)	0.0 ± 0.0	0.0 ± 0.0	0.0 ± 0.0	0.0 ± 0.0
NEUT	($\times 10^2$/μL)	10.3 ± 7.3	7.8 ± 1.6	9.1 ± 5.6	8.2 ± 2.8
LYMPH	($\times 10^2$/μL)	62.4 ± 24.2	60.0 ± 14.7	54.5 ± 15.3	55.1 ± 9.3
MONO	($\times 10^2$/μL)	2.2 ± 0.8	2.2 ± 0.7	2.3 ± 1.0	2.3 ± 0.3
EO	($\times 10^2$/μL)	1.2 ± 0.6	0.9 ± 0.2	1.0 ± 0.2	0.9 ± 0.4
BASO	($\times 10^2$/μL)	0.0 ± 0.0	0.0 ± 0.0	0.0 ± 0.0	0.0 ± 0.0
PT	(sec.)	9.3 ± 0.2	9.5 ± 0.3	9.4 ± 0.2	9.4 ± 0.1
APTT	(sec.)	14.7 ± 0.8	15.4 ± 1.3	15.3 ± 0.8	15.9 ± 0.9

Values; Mean ± SD.
a); vehicle control, corn oil.
*, **; Significantly different from the control at $p < 0.05$ and $p < 0.01$, respectively.

Table 2. Blood Chemistry data of SD rats treated orally with 2-(2H-benzotriazol-2-yl)-6-dodecyl-4-methylphenol for 90 days.

Dose (mg/kg/day)		0 [a)]	100	300	1000
Male (No. of animals)		10	10	10	10
T-bil	(mg/dL)	0.08 ± 0.02	0.06 ± 0.01	0.06 ± 0.01	0.06 ± 0.01
AST	(IU/L)	89 ± 24	68 ± 18	74 ± 13	79 ± 32
ALT	(IU/L)	37 ± 5	32 ± 5	36 ± 6	49 ± 13
γ-GTP	(IU/L)	0 ± 0	0 ± 0	0 ± 0	0 ± 1
ALP	(IU/L)	296 ± 50	306 ± 77	317 ± 61	333 ± 55
TP	(g/dL)	6.2 ± 0.3	6.1 ± 0.2	6.1 ± 0.1	6.1 ± 0.3
A/G		1.16 ± 0.08	1.19 ± 0.08	1.19 ± 0.07	1.16 ± 0.08
Alb	(g/dL)	3.3 ± 0.1	3.3 ± 0.1	3.3 ± 0.1	3.30 ± 0.1
Glb	(g/dL)	2.9 ± 0.2	2.8 ± 0.2	2.8 ± 0.1	2.8 ± 0.2
T-cho	(mg/dL)	73 ± 12	65 ± 8	68 ± 16	79 ± 12
TG	(mg/dL)	85 ± 30	85 ± 38	68 ± 18	71 ± 36
Glu	(mg/dL)	221 ± 32	226 ± 27	212 ± 35	204 ± 21
BUN	(mg/dL)	13.8 ± 1.9	14.9 ± 2.8	15.1 ± 2.2	16.6 ± 3.1
Crea	(mg/dL)	0.31 ± 0.03	0.3 ± 0.03	0.33 ± 0.03	0.33 ± 0.05
Na	(mmol/L)	142 ± 0	143 ± 1**	144 ± 1**	144 ± 1**
K	(mmol/L)	4.8 ± 0.3	4.9 ± 0.3	4.8 ± 0.2	4.7 ± 0.2
Cl	(mmol/L)	102 ± 2	102 ± 1	104 ± 1*	104 ± 2**
Ca	(mg/dL)	10.3 ± 0.3	10.3 ± 0.3	10.2 ± 0.2	10.3 ± 0.3
IP	(mg/dL)	6.0 ± 0.3	5.9 ± 0.5	6.1 ± 0.3	5.9 ± 0.5
Mg	(mg/dL)	1.89 ± 0.11	1.94 ± 0.15	1.92 ± 0.15	1.9 ± 0.17
PL	(mg/dL)	113 ± 17	103 ± 13	103 ± 18	116 ± 15
Serum protein electrophoresis					
Alb	(%)	49.8 ± 2.1	49.9 ± 1.6	50.3 ± 2.4	49.6 ± 1.7
α1	(%)	24.4 ± 2.1	25.4 ± 1.8	23.4 ± 3.3	23.9 ± 0.8
α2	(%)	4.2 ± 0.5	4.6 ± 0.4	5.2 ± 0.6**	4.8 ± 0.5*
β	(%)	4.2 ± 0.3	3.9 ± 0.4	3.8 ± 0.3	3.2 ± 0.6**
γ	(%)	17.5 ± 1.6	16.2 ± 1.8	17.4 ± 2.0	18.5 ± 1.7
Female (No. of animals)		10	10	10	10
T-bil	(mg/dL)	0.09 ± 0.03	0.09 ± 0.03	0.07 ± 0.02	0.07 ± 0.01
AST	(IU/L)	80 ± 10	83 ± 21	88 ± 14	95 ± 21
ALT	(IU/L)	29 ± 5	29 ± 7	29 ± 6	32 ± 8
γ-GTP	(IU/L)	2 ± 1	1 ± 1	1 ± 0	1 ± 1
ALP	(IU/L)	166 ± 52	137 ± 32	159 ± 46	155 ± 51
TP	(g/dL)	6.6 ± 0.3	6.4 ± 0.3	6.4 ± 0.3	6.7 ± 0.4
A/G		1.29 ± 0.12	1.27 ± 0.03	1.29 ± 0.05	1.28 ± 0.05
Alb	(g/dL)	3.7 ± 0.2	3.6 ± 0.1	3.6 ± 0.2	3.8 ± 0.2
Glb	(g/dL)	2.9 ± 0.2	2.8 ± 0.1	2.8 ± 0.1	3.0 ± 0.2
T-cho	(mg/dL)	71 ± 9	81 ± 11	75 ± 15	85 ± 17
TG	(mg/dL)	54 ± 32	70 ± 42	37 ± 12	54 ± 34
Glu	(mg/dL)	182 ± 34	182 ± 23	167 ± 27	180 ± 21
BUN	(mg/dL)	17.4 ± 3.8	14.2 ± 2.0	17.2 ± 2.8	19.1 ± 5.1
Crea	(mg/dL)	0.38 ± 0.1	0.37 ± 0.03	0.37 ± 0.06	0.41 ± 0.07
Na	(mmol/L)	142 ± 1	143 ± 1	144 ± 1	144 ± 2*
K	(mmol/L)	4.3 ± 0.3	4.6 ± 0.3	4.5 ± 0.3	4.8 ± 0.3**
Cl	(mmol/L)	104 ± 1	105 ± 1	106 ± 2	105 ± 2
Ca	(mg/dL)	10.4 ± 0.3	10.3 ± 0.3	10.1 ± 0.2	10.3 ± 0.3
IP	(mg/dL)	4.5 ± 1.0	4.5 ± 0.5	4.7 ± 0.6	5.1 ± 0.8
Mg	(mg/dL)	2.11 ± 0.15	2.01 ± 0.15	2.06 ± 0.09	2.24 ± 0.15
PL	(mg/dL)	134 ± 15	147 ± 18	126 ± 20	145 ± 31
Serum protein electrophoresis					
Alb	(%)	57.7 ± 3.0	56.4 ± 1.6	56.8 ± 2.4	56.8 ± 2.4
α1	(%)	17.2 ± 1.4	19.7 ± 1.1**	18.3 ± 1.5	17.8 ± 2.2
α2	(%)	3.8 ± 0.3	3.9 ± 0.5	3.9 ± 0.6	3.4 ± 0.4
β	(%)	2.6 ± 0.4	2.6 ± 0.7	2.3 ± 0.4	2.4 ± 0.6
γ	(%)	18.7 ± 2.4	17.4 ± 1.6	18.8 ± 2.2	19.5 ± 1.9

Values; Mean ± SD.

a); vehicle control, corn oil.

*, **; Significantly different from the control at $p < 0.05$ and $p < 0.01$, respectively.

Table 3. Organ weight of SD male rats treated orally with 2-(2H-benzotriazol-2-yl)-6-dodecyl-4-methylphenol for 90 days.

Dose (mg/kg/day)	0 [a)]	100	300	1000
Male (No. of animals)	10	10	10	10
Body weight (g)	610.9 ± 53.0	579.9 ± 32.0	587.4 ± 73.6	564.3 ± 44.2
Absolute (g)				
Brain	2.1663 ± 0.0612	2.1133 ± 0.0664	2.1824 ± 0.0846	2.1231 ± 0.0762
Pituitary	0.0161 ± 0.002	0.0151 ± 0.0020	0.0154 ± 0.0022	0.0166 ± 0.0034
Heart	1.5775 ± 0.0983	1.5845 ± 0.1063	1.6090 ± 0.164	1.5837 ± 0.0771
Thymus	0.3204 ± 0.0818	0.3247 ± 0.0718	0.3012 ± 0.0888	0.2859 ± 0.0787
Lungs	1.6137 ± 0.0902	1.5465 ± 0.0900	1.6300 ± 0.1583	1.6049 ± 0.1341
Thyroids	0.0364 ± 0.0058	0.0441 ± 0.0094	0.0464 ± 0.0106*	0.0407 ± 0.0050
Spleen	0.7329 ± 0.1225	0.7649 ± 0.1354	0.7986 ± 0.1160	0.7873 ± 0.1027
Liver	16.8072 ± 1.9306	16.7318 ± 1.9254	15.4901 ± 2.3742	15.3456 ± 1.7290
Kidneys	3.4925 ± 0.2858	3.2121 ± 0.1994	3.4487 ± 0.4962	3.4738 ± 0.3850
Salivary glands	0.7648 ± 0.0783	0.7086 ± 0.0517	0.8007 ± 0.0971	0.8214 ± 0.1030
Adrenals	0.0560 ± 0.0083	0.0537 ± 0.0040	0.0572 ± 0.0096	0.0555 ± 0.0069
Prostate	1.5703 ± 0.4623	1.6425 ± 0.2868	1.9143 ± 0.2611	1.7166 ± 0.3675
Testes	3.7352 ± 0.1761	3.3744 ± 0.2221	3.5846 ± 0.4035	3.5751 ± 0.2684
Seminal vesicle	1.8775 ± 0.3085	1.6558 ± 0.1445	1.8128 ± 0.3075	1.7912 ± 0.2380
Rerative (%)				
Brain	0.3573 ± 0.0352	0.3654 ± 0.0224	0.3766 ± 0.0470	0.3782 ± 0.0310
Pituitary	0.0026 ± 0.0002	0.0026 ± 0.0004	0.0026 ± 0.0004	0.0029 ± 0.0005
Heart	0.2595 ± 0.0222	0.2737 ± 0.0194	0.2751 ± 0.0191	0.2817 ± 0.0186
Thymus	0.0520 ± 0.0092	0.0561 ± 0.0124	0.0511 ± 0.0127	0.0513 ± 0.0160
Lungs	0.2654 ± 0.0216	0.2670 ± 0.0145	0.2789 ± 0.0206	0.2851 ± 0.0226
Thyroids	0.0060 ± 0.0010	0.0076 ± 0.0016*	0.0080 ± 0.0018**	0.0072 ± 0.0008
Spleen	0.1202 ± 0.0194	0.1317 ± 0.0211	0.1363 ± 0.0156	0.1401 ± 0.0199
Liver	2.7468 ± 0.1025	2.8779 ± 0.1913	2.6312 ± 0.1410	2.7161 ± 0.1619
Kidneys	0.5726 ± 0.0309	0.5553 ± 0.0454	0.5865 ± 0.0207	0.6160 ± 0.0508*
Salivary glands	0.1258 ± 0.0154	0.1221 ± 0.0046	0.1370 ± 0.0143	0.1465 ± 0.0225
Adrenals	0.0092 ± 0.0010	0.0093 ± 0.0009	0.0098 ± 0.0014	0.0099 ± 0.0015
Prostate	0.2606 ± 0.0800	0.2841 ± 0.0533	0.3285 ± 0.0444	0.3056 ± 0.0680
Testes	0.6150 ± 0.0563	0.5834 ± 0.0482	0.6151 ± 0.0771	0.6353 ± 0.0455
Seminal vesicle	0.3066 ± 0.0361	0.2867 ± 0.0347	0.3115 ± 0.0557	0.3188 ± 0.0443

a); vehicle control, corn oil.
*, **; Significantly different from the control at $p < 0.05$ and $p < 0.01$, respectively.

of hyperthyroidism in general conditions, body weight, or other organ weight such as the liver. The data of thyroid weight in those groups are equivalent to the historical control data of the test facility (0.0067 ± 0.0026 in males; 0.0104 ± 0.0056, mean ± 2SD, %). Taken together, it was considered that the increased thyroid weights were not related to the treatment.

Eosinophilic bodies and hyaline droplets in the proximal renal tubules were observed at all dosage, but only in males. Considering the male-specific significant increase in the α2 protein ratio and histopathological characteristics, the lesions might be derived from α2-microglobulin, an adult male rat-specific protein (Greaves, 2012; Hamamura *et al*., 2017). In this study, the frequency and grade of the change tended to increase in the 1000 mg/kg group. Various chemicals are reported to evoke α2-microglobulin nephropathy, characterized by similar increases in the eosinophilic bodies and hyaline droplets (Dietrich and Swenberg, 1991; Greaves, 2012; Hamamura *et al*., 2017). However, nephropathy induced by α2-microglobulin in male rats cannot be extrapolated to humans (Doi *et al*., 2007). Therefore, the renal changes in this study suggested the α2-microglobulin nephropathy elicited by BTMLP. Although the relative kidney weight of the males in the 1000 mg/kg group was higher than that of the control males, the weight change may be unrelated to the kidney's lesion. The animal showing maximum kidney weight did not show any lesions in this organ.

Table 4. Organ weight of SD female rats treated orally with 2-(2H-benzotriazol-2-yl)-6-dodecyl-4-methylphenol for 90 days.

Dose (mg/kg/day)	0 [a)]	100	300	1000
Female (No. of animals)	10	10	10	10
Body weight (g)	312.0 ± 40.3	336.1 ± 35.4	298.7 ± 24.2	319.5 ± 30.4
Absolute (g)				
Brain	1.9714 ± 0.1002	1.9734 ± 0.0770	2.0074 ± 0.0910	1.9745 ± 0.0542
Pituitary	0.0195 ± 0.0020	0.0206 ± 0.0019	0.0184 ± 0.0030	0.0207 ± 0.0031
Heart	1.0123 ± 0.0631	1.0449 ± 0.0723	0.9983 ± 0.0535	1.0255 ± 0.0590
Thymus	0.2553 ± 0.0637	0.2858 ± 0.0974	0.3007 ± 0.0910	0.3098 ± 0.0857
Lungs	1.2672 ± 0.1247	1.3247 ± 0.1136	1.2571 ± 0.0777	1.3160 ± 0.1354
Thyroids	0.0434 ± 0.0077	0.0327 ± 0.0046**	0.0322 ± 0.0040**	0.0394 ± 0.0051
Spleen	0.5188 ± 0.0477	0.5557 ± 0.0842	0.5107 ± 0.0800	0.5179 ± 0.0353
Liver	8.1633 ± 1.0789	9.0743 ± 0.9775	8.2780 ± 0.8482	9.1488 ± 0.8887
Kidneys	2.0206 ± 0.1976	2.0598 ± 0.1591	2.0322 ± 0.2068	2.0671 ± 0.1649
Salivary glands	0.5311 ± 0.0472	0.5278 ± 0.0473	0.5085 ± 0.0465	0.5329 ± 0.0451
Adrenals	0.0704 ± 0.0095	0.0672 ± 0.0102	0.0733 ± 0.0089	0.0718 ± 0.0090
Uterus	0.6047 ± 0.1190	0.6022 ± 0.1600	0.5878 ± 0.1340	0.6044 ± 0.1440
Ovaries	0.1428 ± 0.0239	0.1402 ± 0.0152	0.1421 ± 0.0195	0.1414 ± 0.0217
Rerative (%)				
Brain	0.6383 ± 0.0635	0.5937 ± 0.0711	0.6751 ± 0.0511	0.6225 ± 0.0554
Pituitary	0.0063 ± 0.0008	0.0062 ± 0.0008	0.0062 ± 0.0009	0.0065 ± 0.0010
Heart	0.3270 ± 0.0253	0.3131 ± 0.0306	0.3357 ± 0.0274	0.3224 ± 0.0199
Thymus	0.0825 ± 0.0215	0.0853 ± 0.0280	0.0998 ± 0.0261	0.0976 ± 0.0279
Lungs	0.4088 ± 0.0373	0.3972 ± 0.0467	0.4234 ± 0.0434	0.4135 ± 0.0416
Thyroids	0.0139 ± 0.0017	0.0098 ± 0.0014**	0.0108 ± 0.0012**	0.0125 ± 0.0025
Spleen	0.1675 ± 0.0167	0.1660 ± 0.0243	0.1708 ± 0.0210	0.1635 ± 0.0205
Liver	2.6220 ± 0.2048	2.7053 ± 0.1849	2.7724 ± 0.1965	2.8740 ± 0.2644
Kidneys	0.6515 ± 0.0562	0.6162 ± 0.0505	0.6824 ± 0.0714	0.6511 ± 0.0703
Salivary glands	0.1719 ± 0.0204	0.1586 ± 0.0225	0.1709 ± 0.0177	0.1679 ± 0.0187
Adrenals	0.0229 ± 0.004	0.0202 ± 0.0039	0.0246 ± 0.0028	0.0226 ± 0.0028
Uterus	0.1961 ± 0.0443	0.1814 ± 0.0544	0.1972 ± 0.0455	0.1919 ± 0.0570
Ovaries	0.0460 ± 0.0076	0.0421 ± 0.0055	0.0477 ± 0.0060	0.0445 ± 0.0076

Values; Mean ± SD.
a); vehicle control, corn oil.
**; Significantly different from the control at $p < 0.01$.

In conclusion, 2-(2H-benzotriazol-2-yl)-6-dodecyl-4-methylphenol affected blood coagulation and kidney in only males. Judging from the prolongations of PT and APTT, the NOAEL of the test chemical was concluded to be less than 100 mg/kg/day in males and 1000 mg/kg/day in females under this study's conditions.

ACKNOWLEDGMENTS

The authors thank the staff of DSTC for their expert technical assistance in conducting the animal study. This study was supported by MHLW, Japan.

Conflict of interest---- The authors declare that there is no conflict of interest.

Table 5. Histopathological findings of SD male rats treated orally with 2-(2H-benzotriazol-2-yl)-6-dodecyl-4-methylphenol for 90 days.

Dose (mg/kg/day)	0 [a)]				100				300				1000			
Organ: Findings	-	+	++	+++	-	+	++	+++	-	+	++	+++	-	+	++	+++
Lung (Bronchus)	n = 10												n = 10			
Accumulation, foamy cell, alveolar lumen	9	1											8	2		
Heart	n = 10												n = 10			
Accumulation, mononuclear cell, ventricular wall	7	3											9	1		
Liver	n = 10												n = 10			
Vacuolar change, hepatocyte, perilobular	9	1											9	1		
Accumulation, mononuclear cell, Glisson and lobule	7	3											8	2		
Kidney	n = 10				n = 10				n = 10				n = 10			
Eosinophilic body and/ or hyaline droplet, tubular, cortex	6	4			7	1	2		7	1	2		3	4	3	
Basophilic change, tubular, cortex	6	4			9	1			8	2			9	1		
Infarct, cortex	8	2			10				9	1			10			
Cyst, medulla	9	1			9	1			10				9	1		
Pituitary	n = 10												n = 10			
Craniopharyngeal duct remnant	10												9	1		
Cyst, anterior lobe, single	9	1											9	1		
Thyroid	n = 10												n = 10			
Ultimobranchial remnant	9	1											8	2		
Ectopic thymus	10												9	1		
Eye ball (optic nerve)	n = 10												n = 10			
Retinal dysplasia, unilateral	10												9	1		
Prostate	n = 10												n = 10			
Infiltration, lymphocyte, interstitium	7	2	1										8	2		

Data are presented as the number of animals showing each finding.
a); vehicle control, corn oil.
Grade: - No change/Not observed, + Slight, ++ Moderate, +++ Marked.
No significant difference in the nunber of animals showing each microscopic finding.
Cerebrum, Cerebellum, Medulla oblongata, Spinal cord, Submandibular and Sublingual glands, Parotid gland, Submandibular and Mesenteric lymphnodes, Thymus, Tongue, Aorta, Esophagus, Trachea, Spleen, Pancreas, Stomach, Duodenum, Jejunum, Ileum, Cecum, Colon, Rectum, Adrenal gland, Parathyloid, Harderian gland, Sciatic nerve, Skin (mammary gland), Thigh muscle, Testis, Epididymedis, Seminal vesicle, Urinary bladder, Femur and Sternum (bone marrow), Nasal cavity, and Zymbal's gland were not observed any changes related to the treatment of the test chemical.

Table 6. Histopathological findings of SD female rats treated orally with 2-(2H-benzotriazol-2-yl)-6-dodecyl-4-methylphenol for 90 days.

Dose (mg/kg/day)	0 [a)]				1000			
Organ: Findings	-	+	++	+++	-	+	++	+++
Liver	n = 10				n = 10			
Vacuolar change, hepatocyte, perilobular	9	1			9	1		
Accumulation, mononuclear cell, Glisson and lobule	7	3			7	3		
Focal necrosis, hepatocyte	10				9	1		
Kidney	n = 10				n = 10			
Mineralization, medulla	9	1			10			
Thyroid	n = 10				n = 10			
Ultimobranchial remnant	8	2			6	4		

Data are presented as the number of animals showing each finding.
a); vehicle control, corn oil.
Grade: - No change/Not observed, + Slight, ++ Moderate, +++ Marked.
No significant difference in the nunber of animals showing each microscopic finding.
Cerebrum, Cerebellum, Medulla oblongata, Spinal cord, Sublingual and Sublingual glands, Parotid gland, Submandibular and Mesenteric lymphnodes, Thymus, Tongue, Lung (Bronchus), Heart, Aorta, Esophagus, Trachea, Spleen, Pancreas, Stomach, Duodenum, Jejunum, Ileum, Cecum, Colon, Rectum, Pituitary, Adrenal gland, Parathyloid, Eye ball (optic nerve), Harderian gland, Sciatic nerve, Skin (mammary gland), Thigh muscle, Ovary, Oviduct, Uterus, Vagina, Urinary bladder, Femur and Sternum (bone marrow), Nasal cavity, and Zymbal's gland were not observed any changes related to the treatment of the test chemical.

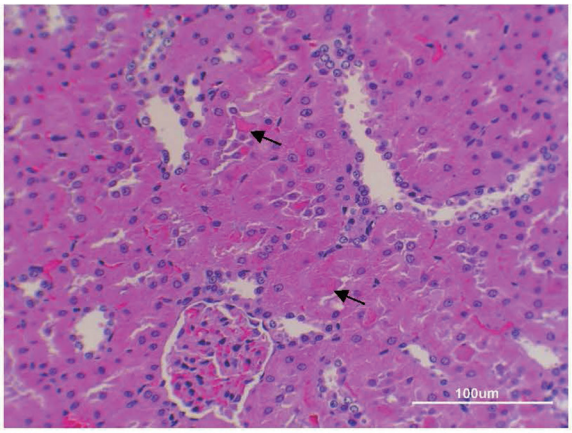

A. Control

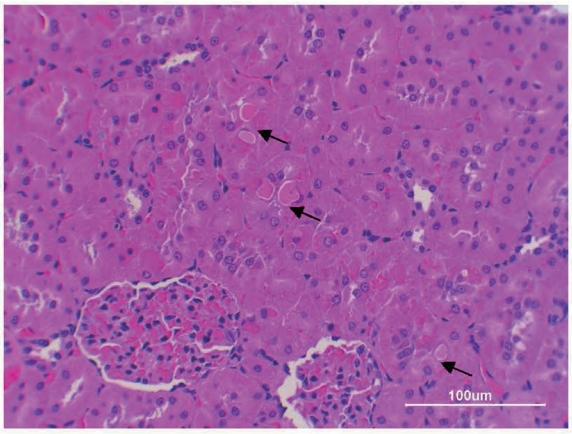

B. 1000 mg/kg treated group

Fig. 4. Representative findings in the analysis of kidneys of male SD rats treated orally with 2-(2H-benzotriazol-2-yl)-6-dodecyl-4-methylphenol for 90 days. Hematoxylin and eosin stain. Arrows showed the alternative renal epithelial cells resulting from eosinophilic bodies and hyaline droplets in males. These were observed in only males regardless of the dose levels including the control group (A). In the 1000 mg/kg group in males, the frequency and degree of the deposits tended to increase (B).

REFERENCES

Diehl, K.H., Hull, R., Morton, D., Pfister, R., Rabemampianina, Y., Smith, D., Vidal, J.M. and van de Vorstenbosch, C. (2001): A good practice guide to the administration of substances and removal of blood, including routes and volumes. J. Appl. Toxicol., **21**, 15-23.

Dietrich, D.R. and Swenberg, J.A. (1991): The presence of alpha 2u-globulin is necessary for d-limonene promotion of male rat kidney tumors. Cancer Res., **51**, 3512-3521.

Doi, A., Hill, G., Seely, J., Hailey, J.R., Kissling, G. and Bucher, J.R. (2007): α2u-Globulin nephropathy and renal tumors in National Toxicology Program studies. Toxicol. Pathol., **35**, 533-540.

Greaves, P. (2012): Urinaly Tract, Kidney In *Histopathology of Preclinical Toxicity studies*, pp. 537-614. London, U.K.: Academic Press.

Hamamura, M., Oshikata, T., Katoku, K., Tsuchitani, M. and Yamaguchi, R. (2017): Two types of deposits, hyaline droplets and eosinophilic bodies, associated with α_{2u}-globulin accumulation in the rat kidney. J. Toxicol. Pathol., **30**, 275-282.

Watanabe, Y., Hattori, S., Fujino, C., Tachibana, K., Kojima, H., Yoshinari, K. and Kitamura, S. (2019): Effects of benzotriazole ultraviolet stabilizers on rat PXR, CAR and PPARα transcriptional activities. Fundam. Toxicol. Sci., **6**, 57-63.